

CASE REPORT

A Novel Two-Stage Surgical Approach to Treat Chronic Lymphedema

Jay W. Granzow, MD, MPH, FACS,* Julie M. Soderberg, MPT, ATC, CSCS, CLT-LANA,[†] and Christine Dauphine, MD, FACS*

*Harbor-UCLA Medical Center and the UCLA David Geffen School of Medicine, Los Angeles, California; [†]Providence Little Company of Mary Hospital, Torrance, California

■ **Abstract:** Surgical treatment of chronic lymphedema has seen significant advances. Suction-assisted protein lipectomy (SAPL) has been shown to safely and effectively reduce the solid component of swelling in chronic lymphedema. However, these patients must continuously use compression garments to control and prevent recurrence. Microsurgery procedures, including lymphaticovenous anastomosis (LVA) and vascularized lymph node transfer (VLNT), have been shown to be effective in the management of the fluid component of lymphedema and allow for decreased garment use. SAPL and VLNT were applied together in a two-stage approach in two patients with chronic lymphedema after treatment for breast cancer. SAPL was used first to remove the chronic, solid component of the soft-tissue excess. Volume excess in our patients' arms was reduced an average of approximately 83% and 110% after SAPL surgery. After the arms had sufficiently healed and the volume reductions had stabilized, VLNT was performed to reduce the need for continuous compression and reduce fluid re-accumulation. Following the VLNT procedures, the patients were able to remove their compression garments consistently during the day and still maintain their volume reductions. Neither patient had any postoperative episodes of cellulitis. SAPL and VLNT can be combined to achieve optimal outcomes in patients with chronic lymphedema. ■

Key Words: lymphaticovenous anastomosis, lymphedema, SAPL, Suction-assisted protein lipectomy, vascularized lymph node transfer

Lymphedema is a common problem affecting approximately one in five patients who survive breast cancer (1). The first surgical approaches to manage chronic lymphedema consisted of massive debulking of the accumulated proteinaceous fatty solid mass from the affected extremity through wide excision. A century later, these solids can be removed safely using a minimally invasive technique known as suction-assisted protein lipectomy (SAPL). Although this technique is able to remove the bulk of the excess soft-tissue volume and reduce infection risk by over 75%, patients must continue to wear custom-fit compression garments to maintain satisfactory results (2).

We present the first description of two patients in whom vascularized lymph node transfer (VLNT) was performed as a second-stage microvascular procedure

after SAPL to restore lymphatic drainage from the limb and greatly reduce the need for ongoing compression garment use.

Case 1

A 55-year-old woman presented with a 4-year history of lymphedema after undergoing a left lumpectomy and axillary lymph node dissection, followed by radiation therapy to the ipsilateral axilla and chest wall for breast cancer. The lymphedema arm swelling in the left side began during chemotherapy, and worsened despite the use of complete decongestive lymphedema therapy (CDT) and continuous daily use of a compression garment. (Fig. 1a) She had decreased function of her left arm, which significantly hindered her ability to play golf and perform activities of daily living such as hair washing.

On examination, she had nonpitting lymphedema of the left arm with a calculated volume excess of 1142 cc. SAPL was performed, and the patient achieved a stable volume reduction of 90–100% such that the size of the affected left arm became almost

Address correspondence and reprint requests to: Jay W. Granzow, MD, MPH, FACS, Associate Professor of Surgery, UCLA Division of Plastic Surgery, Harbor-UCLA Medical Center, 1000 West Carson Street, Box 25, Torrance, CA 90509, USA, or e-mail: drjay@plasticsurgery.ucla

DOI: 10.1111/tbj.12282

© 2014 Wiley Periodicals, Inc., 1075-122X/14
The Breast Journal, 2014 1–3

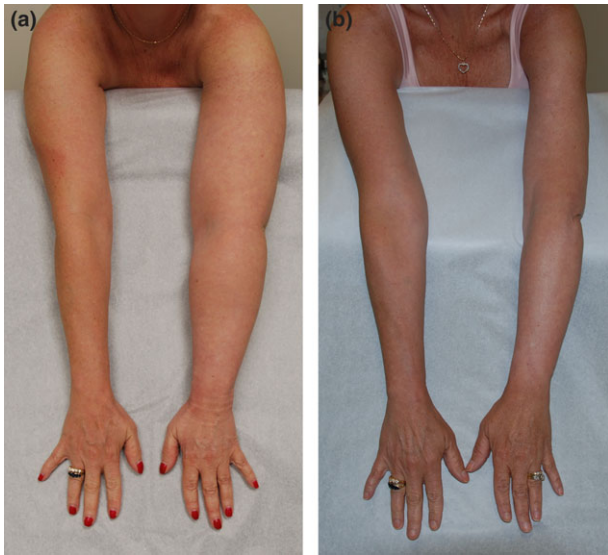

Figure 1. (a) Patient 1 with 4-year history of chronic, non-compressible lymphedema of the left arm after maximum reduction possible with conservative therapy. (b) Patient 1 following staged SAPL and VLNT.

identical to the unaffected right side. However, maintenance of the volume reduction required continuous compression to prevent fluid reaccumulation.

Eleven months after SAPL, VLNT from the right groin to the left axilla was performed. Postoperatively, the patient was able to reduce compression garment use to evenings and nighttime only, while maintaining an overall stable volume reduction between 75 and 90%. She has had no episodes of cellulitis after surgery. Furthermore, she has resumed playing golf, with no ongoing problems with activities of daily living. (Fig. 1b).

Case 2

A 63-year-old woman presented with a 19-year history of lymphedema following right lumpectomy, axillary lymph node dissection, and radiation therapy for breast cancer. One year after completing her cancer therapies, the patient developed lymphedema of the right arm, which was poorly treated at the time. She then developed contralateral breast cancer 11 years later, and was treated with lumpectomy, sentinel lymph node biopsy, and radiation therapy. The patient subsequently tested positive for a BRCA2 gene mutation, but declined bilateral mastectomies at that time. Since developing right upper extremity lymphedema, she had been hospitalized for repeated episodes of right arm cellulitis requiring intravenous antibiotic

treatment and was placed on daily oral antibiotic prophylaxis along with continual use of a compression garment to prevent further infections and volume increase. (Fig. 2a)

On examination, she had nonpitting lymphedema of the right arm with a calculated volume excess of 898 cc. SAPL was performed with a stable volume reduction achieved between 97 and 107%. No further infections occurred, and prophylactic antibiotics were discontinued.

Twenty-two months after SAPL, the patient opted to undergo bilateral prophylactic mastectomies. Breast reconstruction was performed with bilateral DIEP flaps and VLNT on the right side. Following surgery, the patient and physician noted a significant subjective improvement in the lightness of the arm and the ability to see bony and tendinous landmarks much more clearly. A stable volume reduction between 108 and 113% was maintained with use of a compression garment mainly at nighttime. The patient had no further infections and was able to stop antibiotic prophylaxis completely. (Fig. 2b)

DISCUSSION

To our knowledge, we present the first description of a two-stage approach to treat chronic lymphedema. SAPL was used in the first stage to remove the chronically accumulated proteinaceous and fatty tissues. However, both patients required continuous use of compression garments to prevent reaccumulation of lymphatic fluid. After undergoing subsequent VLNT,

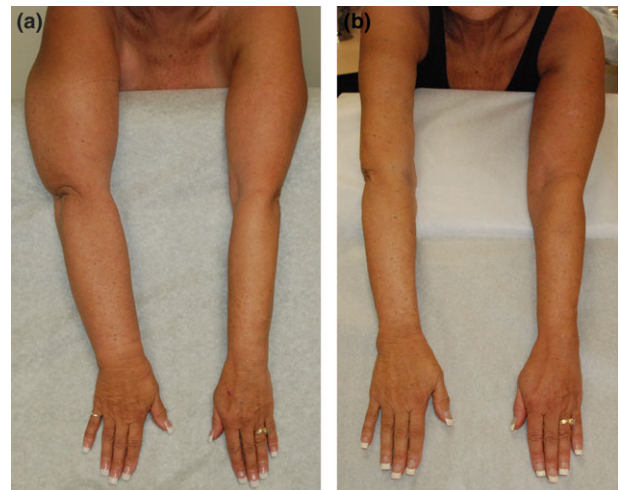


Figure 2. (a) Patient 2 with 19-year history of chronic, non-compressible lymphedema of right arm. (b) Patient 2 following staged SAPL and bilateral DIEP flap breast reconstruction with VLNT.

both patients experienced a significant reduction in the need for compression garment use for much of the daytime.

SAPL is performed by aspirating the excess proteinaceous fatty tissue from the affected limb using power-assisted liposuction cannulas in a technique similar to that described previously by Brorson (2). We have previously reported the success of SAPL, with one-year reductions in volume excess of 929 cc (111% average reduction) in arms and 3731 cc (86% average reduction) in legs (3). Furthermore, the incidence of dangerous cellulitis was reduced by over 75%. The safety and efficacy of the surgery have been well established in prospective long-term studies, and found not to further damage the already impaired lymphatic flow in the affected patients studied (4–6).

A chief limitation of SAPL has been the requirement for ongoing use of compression garments after surgery to prevent reaccumulation of lymphatic fluid (7). Integral lymphedema therapist involvement both before and after surgery is mandatory for the success of the technique. The therapist measures each patient preoperatively for a set of custom-fit, flat knit compression garments. One set of garments is donned immediately at the time of surgery, and additional, custom-fit layers are placed as needed by the lymphedema therapist during the postoperative hospital stay. The average hospital stay is two days, and patients are seen in the office the week following discharge. As the swelling decreases over time, the compression garments are either taken in or replaced with new, smaller custom-fit garments. The technique and patient care required for SAPL is different than cosmetic liposuction, and should only be performed by surgeons experienced in the care of lymphedema patients and specifically trained in the technique (8).

Compression garments can be cumbersome, unsightly, hot, and restrictive to movement. They are often quite visible and carry the stigma of having lymphedema. However, they are required postoperatively to preserve the dramatic reductions in excess volume and infection risk achieved through SAPL. While patients may eventually leave the garment off for a few hours to attend a special event, prompt replacement afterward is necessary. Removal of the garments for a significant period of time on a routine basis will allow for reaccumulation of lymphedema fluid.

VLNT as a second-stage procedure was performed to restore lymphatic drainage and to reduce the need for compression garment use. VLNT involves the transfer

of lymph nodes from one lymph node basin to another on a microvascular pedicle, anastomosing at least one donor artery and vein to vessels at the recipient site. The lymphatics and small peripheral vessels in the flap are allowed to heal primarily with the lymphatics and small vessels present in the recipient soft-tissue bed (9).

We perform SAPL and VLNT procedures in a staged fashion. This allows the postoperative swelling, which occurs after the SAPL procedure, to subside and the limb to heal completely. The gradual reduction in swelling after SAPL typically takes about 6 to 12 months to reach a steady state, and after this time VLNT can be performed.

To conclude, SAPL is a validated surgical approach to treat chronic lymphedema. SAPL primarily addresses the solid component of the disease, but requires continuous use of compression garments to prevent recurrence. In well-selected patients suffering from chronic lymphedema, VLNT can be combined with SAPL in a two-stage approach to improve fluid drainage and reduce excess limb volume, risk of dangerous infections, and need for continuous compression garment use.

COMMERCIAL INTERESTS

None.

REFERENCES

1. DiSipio T, Rye S, Newman B, Hayes S. Incidence of unilateral arm lymphoedema after breast cancer: a systematic review and meta-analysis. *Lancet Oncol* 2013;14:500–15.
2. Brorson H, Ohlin K, Svensson B. The facts about liposuction as a treatment for lymphoedema. *J Lymphoedema* 2008;3:38–47.
3. Granzow JW, Soderberg JM, Kaji AH, Dauphine C. An effective system of surgical treatment of lymphedema. *Ann Surg Oncol* 2014;21:1189–94.
4. Brorson H, Freccero C, Ohlin K, Svensson B. Liposuction of postmastectomy arm lymphedema completely removes excess volume: A 15 year study. *Lymphology* 2010;43(Suppl):108–10.
5. Brorson H, Ohlin K, Olsson G, Svensson B. Liposuction normalized elephantiasis of the leg: a prospective study. *Eur J Lymphol* 2007;17:8.
6. Brorson H, Svensson H, Norrgren K, Thorsson O. Liposuction reduces arm lymphedema without significantly altering the already impaired lymph transport. *Lymphology* 1998;31:156–72.
7. Brorson H. From lymph to fat: liposuction as a treatment for complete reduction of lymphedema. *Int J Low Extrem Wounds* 2012;11:10–9.
8. Granzow JW, Soderberg JM, Kaji AH, Dauphine C. Review of current surgical treatments for lymphedema. *Ann Surg Oncol* 2014;21:1195–201.
9. Becker C, Assouad J, Riquet M, Hidden G. Postmastectomy lymphedema: long-term results following microsurgical lymph node transplantation. *Ann Surg* 2006;243:313–5.